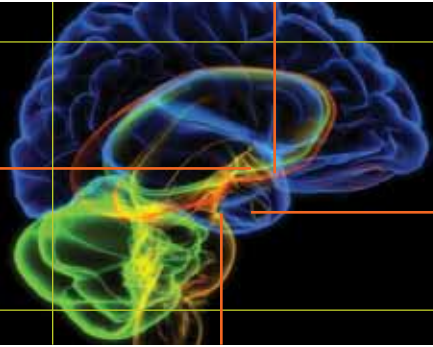


## PATIENT INFORMATION

**UT SOUTHWESTERN**  
MEDICAL CENTER



© 2013 UT Southwestern Medical Center, MKG 305.3

Comprehensive Skull Base Program • 214-645-3400 • [utswmedicine.org/skullbase](http://utswmedicine.org/skullbase)

### CEREBROSPINAL FLUID (CSF) LEAK

#### Introduction:

Cerebrospinal fluid fistula, commonly known as CSF leak, occurs when there is an abnormal communication between the CSF containing space around the brain (subarachnoid space) and either the sinuses or the ear. In general, the brain is a sterile compartment and is separated from the sinuses and the ear by a bony separation called the skull base. Cerebrospinal fluid surrounds the brain and cushions it. A thick, leathery tissue called dura mater (or just "dura," for short) lines the inside of the skull. Dura provides a waterproof seal that prevents spinal fluid from escaping. CSF leaks occur when there is a breakdown of this barrier.

CSF leaks may be recognized as clear drainage coming from the nose (CSF rhinorrhea) or the ear (CSF otorrhea). CSF leaks most commonly occur from trauma or surgery; however, they can also occur spontaneously without an identifiable cause. Untreated CSF leaks can represent a potentially life threatening situation leading to meningitis, brain infection, stroke and death. Thus, timely diagnosis and repair is warranted to minimize this risk. In the past, repair often required brain surgery, but now many cases of CSF rhinorrhea can be repaired by working through the nose and sinuses with endoscopic instruments (i.e., no external incisions).

#### CSF Rhinorrhea:

CSF rhinorrhea results due to a breakdown of the barrier separating the spinal fluid space from the nose and sinuses. The usual symptom is watery, nasal drainage coming from either the left or right side of the nose. The drainage will often worsen upon leaning forward or with strenuous activity. Less commonly, there is no drainage and the CSF leak may be discovered only after repeated episodes of meningitis.


#### Potential Causes:

CSF rhinorrhea can occur for a variety of reasons. Most commonly, the leak will arise following trauma or surgery. A variety of operations, including endoscopic sinus, nasal, and neurosurgical procedures, can result in a CSF leak. Trauma caused by blunt head injury, like car accidents, or penetrating head injury from gunshot wounds or from other sharp objects can also result in a CSF leak. Conditions that can raise the pressure around the brain (intracranial pressure [ICP]), such as brain and skull base tumors can also cause leaks. Spontaneous CSF leaks are increasingly common and now recognized as a distinct clinical entity often seen in obese, middle-aged females. Spontaneous CSF leaks may be associated with elevated spinal fluid pressure resulting in bone thinning in key areas of the sinuses (sphenoid sinus, cribriform plate), and, eventually causing bone erosion with CSF leakage or brain herniation.

#### CSF Otorrhea:

CSF otorrhea results from a breakdown of the barrier separating the middle ear from the spinal fluid spaces of the brain. When present, watery fluid drips or flows out of the ear.

CSF otorrhea can also result from trauma. It is especially common after fractures which involve the base of the skull. CSF leakage from the ear following trauma often resolves spontaneously within 1-2 weeks. If not, surgical correction is required. Spinal fluid leakage into the middle ear or mastoid



*continued*

Comprehensive Skull Base Program • 214-645-3400 • [utswmedicine.org/skullbase](http://utswmedicine.org/skullbase)

can also follow various types of surgery – most commonly, it follows operations designed to remove tumors like acoustic neuromas. Just like cerebrospinal fluid rhinorrhea, cerebrospinal fluid otorrhea can occur spontaneously. It too appears to be associated with increased intracranial pressure and is most often encountered in overweight individuals.

## Diagnostic Testing:

The diagnosis of CSF leaks requires a high index of suspicion as the presenting symptoms are often non-specific. An array of tests can be performed to help confirm the diagnosis of CSF leak and to accurately pinpoint its location. A surgeon can pick the best diagnostic strategy to help identify the leak and to formulate the surgical plan.

**1. Beta2-transferrin:** Nasal secretions can be tested for beta2-transferrin, a protein found in spinal fluid. This is a highly specific and non-invasive method of confirming the presence of CSF leak.

**2. Nasal endoscopy:** A small, slender, flexible or rigid tube attached to a camera is used to examine the inside of the nose. In many cases, the area of leakage or herniated brain tissue (encephalocele) may be identified.

**3. CT (computed tomography) scan:** This is the best radiologic study to diagnose CSF leaks. Fine cut (1-mm) CT scan provides a detailed view of the bony anatomy of the nasal sinuses to help identify the site of leakage. The scan may show a small defect or fracture in the bone of the skull base (cribriform plate, sphenoid sinus). In selected cases, contrast may be injected into the spinal fluid through a spinal tap to help identify the site of leakage (CT cisternogram).

**4. MRI (magnetic resonance imaging) scan:** This provides a detailed view of the soft tissue anatomy of the sinuses and the brain compartment. This may be required in selected cases to determine the contents of herniated tissue (brain or meninges [covering of the brain]) or to evaluate for specific conditions associated with CSF leaks, such as empty sella syndrome.


**5. Pledget study:** This is also known as radionuclide cisternography. This study involves placement of small cotton pads inside the nose to confirm the presence of a CSF leak. It was more popular prior to the era of modern imaging. Typically, this test can identify the presence but not the exact location of the leak.

## Management:

A treatment strategy is devised taking into account the cause and the location of the leak. Most CSF leaks will require timely surgical repair to minimize the risk of brain infection or meningitis. Traditional techniques required a craniotomy (opening in the skull bone) or external facial incisions to fix the leak. But now, with advanced endoscopic techniques, most nasal CSF leaks arising from the sinuses can be fixed working through the nose with small scopes and instruments. CSF leaks from the ear usually require an external incision.

## Endoscopic CSF leak repair:

The endoscopic approach represents the preferred surgical technique for management of sinus CSF leaks. It is associated with a success rate approaching 90-95% with the initial attempt and carries far less morbidity than the open skull approaches. The surgery entails separation of the communication from the nose and sinuses to the brain compartment. The otolaryngologist will use the endoscope to precisely identify the location of the CSF leak and place small pieces of tissue from the nasal lining (grafts) to achieve the desired result. In select cases, synthetic tissue, cartilage, and/or bone may be required to reinforce the leak area.



*continued*

Comprehensive Skull Base Program • 214-645-3400 • [utswmedicine.org/skullbase](http://utswmedicine.org/skullbase)

## **Repair of CSF Otorrhea:**

Endoscopic techniques have not been widely applied to CSF otorrhea. Most operations for the control of CSF otorrhea still require a surgical incision. If it has been determined that the leak is coming from the posterior fossa (lower intracranial compartment), then the operation can also often be performed through a transmastoid approach.

An incision is made behind the ear, a standard mastoidectomy is performed, and the leak sealed with fat, muscle, calcium-phosphate bone cement, bone wax or methyl methacrylate. This can frequently be done as a day surgery procedure. ICU care is rarely required.

If the leak is coming from the middle cranial fossa, then a middle cranial fossa craniotomy is necessary. An incision is made above the ear and a small window of bone is removed. This bone flap is replaced at the end of the case with very small titanium plates to hold it in position. The middle temporal lobe of the brain is allowed to gently fall away from the bone of the skull base and the site of leaking is identified. The leaking area is then repaired with strips of tissue, with bone chips, bone paste, calcium-phosphate bone cement or packaged, pre-processed graft materials. A middle cranial fossa craniotomy requires 3-4 days in the hospital and at least the first post-operative night is spent in the ICU. Though this operation is performed regularly without incident, serious complications can occur and include bleeding into the brain, the development of a seizure disorder, unilateral deafness and injury to the facial nerve with facial paralysis.

## **Risks of CSF leak repair:**


The risks of CSF leak repair include all risks associated with endoscopic sinus surgery, such as bleeding, scarring, infection, change in smell and taste, or injury to the eye (loss of vision, temporary or prolonged double vision, eye tearing). Although extremely rare, surgical manipulation of the CSF leak site may create a potential for infection spreading from the sinuses to the brain resulting in meningitis. General anesthesia is also associated with occasional but possibly serious risks.

## **Intrathecal fluorescein:**

Intraoperatively, a dye called fluorescein may be used in selected cases. Fluorescein is injected slowly into the spinal fluid and will stain CSF green. This can help accurately localize the site of the leak and ensure successful closure at the conclusion of the surgery. It has been widely used for this purpose in CSF leak repair. Fluorescein is an FDA-approved drug but has not been approved for this specific purpose. The risk of complications is extremely low at dilute concentrations; however, neurologic complications, such as paralysis, seizures, and even death have been reported with high dosages. Please check with your surgeon if fluorescein will be used during the surgery.

## **Spinal (or lumbar) drain:**

In select cases, especially when elevated CSF pressure is suspected, a spinal drain may be required temporarily to help improve the success rate of surgery. A lumbar drain is a small, flexible, catheter that is placed in the lower back to remove spinal fluid. The spinal drain is typically placed during surgery by the neurosurgeon after the patient is already under anesthesia. Although generally a safe procedure, potential complications include infection, bleeding, nerve irritation, paralysis, post-spinal headaches, and pneumocephalus (air entering the brain space).



*continued*

Comprehensive Skull Base Program • 214-645-3400 • [utswmedicine.org/skullbase](http://utswmedicine.org/skullbase)

## **Postoperative care and follow-up:**

Postoperatively, you will be placed on bed rest in the hospital to help facilitate the healing process and to closely monitor for leak recurrence. It is usually important to keep the head elevated. Typical hospital stay will be 2-3 days to confirm successful closure of the leak. In selected cases with use of lumbar drain, longer hospital stay may be required. Each case is individualized and the treatment plan is tailored to ensure long-term success of the surgery. If sutures were placed, they are removed 10-14 days after surgery.

The repair site can take 4 to 6 weeks to achieve complete healing. Activity restriction, including avoidance of straining and heavy lifting (greater than 10 lbs) and no nose blowing are critical. Any constipation in the post-op period is treated with stool softeners. Any fevers greater than 101°F, significant headaches, vision changes, recurrent nasal drainage, or neck stiffness can be serious signs and require immediate attention. Please contact your surgeon immediately during regular business hours or call 911 if the situation requires emergent care.

## **Making an Appointment:**

Primary care physicians typically refer new patients to UT Southwestern Medical Center. If an individual does not need a referral, they may make an appointment through the following options:

- Complete an online Request an Appointment Form.
- Call 214-645-6455 or 866-645-6455 (toll free).

Physicians referring a patient may call our dedicated Skull Base Physician Referral line at 214-645-3400 or

- Complete an online Physician Referral Form.
- Call 866-645-5455 (toll free).

## **After-Hours Care:**

Current UT Southwestern patients who need urgent care outside of normal business hours may call 214-648-3111 to leave a page for our on-call physician.

## **Emergency Care:**

If an individual is experiencing a life-threatening problem, they should call 911 immediately or go to the nearest emergency room. UT Southwestern's emergency room is located at University Hospital-St Paul, 5909 Harry Hines Blvd. (corner of Harry Hines Boulevard and Inwood Road).

**Website:** [www.utsouthwestern.org/skullbase](http://www.utsouthwestern.org/skullbase)